

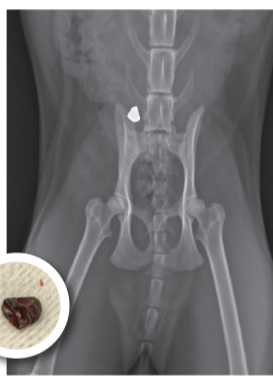


# AIR RIFLE INJURY IN A CAT

Chanel, a beautiful 17 month old Birman arrived home late one Sunday evening with a profusely bleeding wound on her back. Her very concerned owners rushed her to the After hours clinic where she was placed on oxygen, given intravenous fluids and pain relief. The xray taken showed Chanel had been shot with two air rifle pellets – one was sitting in her abdomen and one in her left hind leg. She was also slightly anemic due to blood loss. Miraculously she was still alive. Chanel was operated on to remove the hind leg pellet that night but it was felt too risky to open her up and remove the abdominal pellet due to ongoing blood loss. Thankfully the pellets missed her vital organs and spine.

Chanel arrived at McMaster & Heap Vet Practice on Monday morning in a fairly critical condition. She was closely monitored and her pain medication with a fentanyl patch provided her with continuous relief – being shot would be quite sore!

Chanel had regular blood tests in house to check her vital organs and to be sure her anemia wasn't worsening. Unfortunately she was becoming more anemic. Kirsty performed an abdominal ultrasound and took chest xrays to check for free blood indicating an active bleed. There was also some concern about potential damage to her left kidney from the pellet location. Thankfully through all this her appetite was great!



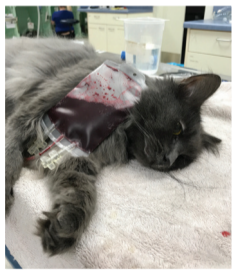and about 60mls of blood was drawn from him to give to Chanel over a couple of hours.

The donor cat has their red cell levels checked and must be Feline Aids (FIV) negative.

The following day Chanel appeared brighter and happier. We decided to wait a further week before operating to make sure her blood levels were stable and that she was producing good numbers of red cells on her own. The repeated ultrasound and xray showed that thankfully her left kidney appeared normal however the bullet had slightly moved.

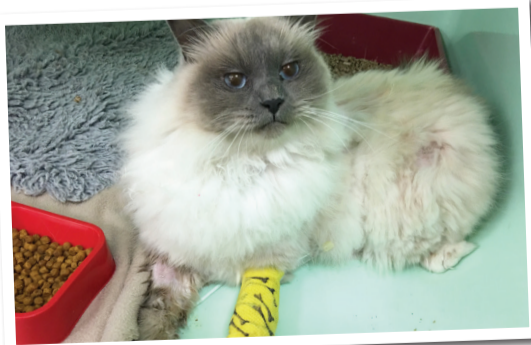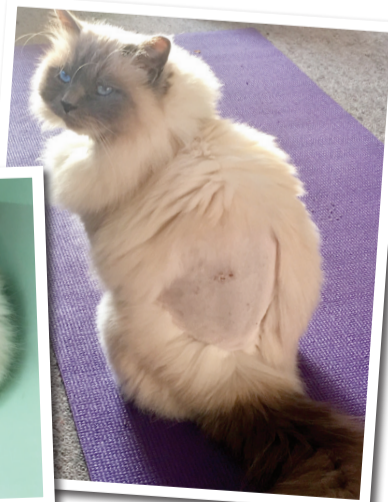Chanel's surgery proceeded without a hitch. The bullet was successfully removed with very little trauma, from just behind her left kidney. That afternoon she was rolling around, playing in her cage, able to be discharged from our hospital. We continued with pain relief and one week later Chanel was near normal. This would have been a completely different story had her abdominal organs been penetrated or her spine shattered. Thanks to her owner's rapid response, Chanel's life was saved and she's never looked back. Also a bonus that her dedicated owners have pet insurance.

Dr Michele McMaster



Prior to her second surgery, it was decided that Chanel would benefit from a blood transfusion to help her red blood cell levels. She was blood typed ( Type A) and found to be

a match for Kirsty's cat "Wolfie". Wolfie was sedated



OPEN 7 DAYS

Cnr Hoon Hay & Coppell Place  
Phone 338 2534, Fax 339 8624

E. mcmasterandheap@yahoo.co.nz  
www.mcmasterheap.co.nz



McMaster & Heap